

## Article

# A Novel Gonadotropic Microsporidian Parasite (*Microsporidium clinchi* n. sp.) Infecting a Declining Population of Pheasantshell Mussels (*Actinonaias pectorosa*) (Unionidae) from the Clinch River, USA

Susan Knowles<sup>1,\*</sup>, Eric M. Leis<sup>2</sup>, Jordan C. Richard<sup>3,4</sup>, Rebecca Cole<sup>1</sup>, Rose E. Agbalog<sup>4</sup>, Joel G. Putnam<sup>5</sup>, Tony L. Goldberg<sup>3</sup> and Diane L. Waller<sup>5</sup>

<sup>1</sup> National Wildlife Health Center, U.S. Geological Survey, Madison, WI 53711, USA; rcole@usgs.gov

<sup>2</sup> La Crosse Fish Health Center-Midwest Fisheries Center, U.S. Fish and Wildlife Service, Onalaska, WI 54650, USA; eric\_leis@fws.gov

<sup>3</sup> Department of Pathobiological Sciences and Freshwater & Marine Sciences Program, University of Wisconsin-Madison, Madison, WI 53711, USA; jcrichard2@wisc.edu (J.C.R.); tony.goldberg@wisc.edu (T.L.G.)

<sup>4</sup> Southwestern Virginia Field Office, U.S. Fish and Wildlife Service, Abingdon, VA 24210, USA; rose\_agbalog@fws.gov

<sup>5</sup> Upper Midwest Environmental Sciences Center, U.S. Geological Survey, La Crosse, WI 54603, USA; jgputnam@usgs.gov (J.G.P.); dwaller@usgs.gov (D.L.W.)

\* Correspondence: sknowles@usgs.gov



**Citation:** Knowles, S.; Leis, E.M.; Richard, J.C.; Cole, R.; Agbalog, R.E.; Putnam, J.G.; Goldberg, T.L.; Waller, D.L. A Novel Gonadotropic Microsporidian Parasite (*Microsporidium clinchi* n. sp.) Infecting a Declining Population of Pheasantshell Mussels (*Actinonaias pectorosa*) (Unionidae) from the Clinch River, USA. *Parasitologia* **2022**, *2*, 1–12. <https://doi.org/10.3390/parasitologia2010001>

Academic Editor: Edit Eszterbauer

Received: 27 October 2021

Accepted: 15 December 2021

Published: 1 January 2022

**Publisher's Note:** MDPI stays neutral with regard to jurisdictional claims in published maps and institutional affiliations.



**Copyright:** © 2022 by the authors. Licensee MDPI, Basel, Switzerland. This article is an open access article distributed under the terms and conditions of the Creative Commons Attribution (CC BY) license (<https://creativecommons.org/licenses/by/4.0/>).

**Abstract:** Freshwater mussels of the order Unionida are among the most endangered animal groups globally, but the causes of their population decline are often enigmatic, with little known about the role of disease. In 2018, we collected wild adult pheasantshell (*Actinonaias pectorosa*) and mucket (*Actinonaias ligamentina*) during an epidemiologic survey investigating an ongoing mussel mass mortality event in the Clinch River, Virginia and Tennessee, USA. Histopathology and transmission electron microscopy showed a novel microsporidian parasite primarily infecting the ovary of pheasantshell. Sequencing of the small subunit rRNA gene produced a 1333 bp sequence with the greatest similarity to *Pseudonosema cristatellae* (AF484694.1; 86.36%; e-value = 0), a microsporidium infecting the freshwater bryozoan (*Cristatella mucedo*). Microsporidia were observed in 65% (17/26) of the examined female pheasantshell (*A. pectorosa*) and in no (0/2) female muckets (*A. ligamentina*) and occurred at mortality and non-mortality sites. Our findings indicate that a novel parasite, *Microsporidium clinchi* n. sp., is present in pheasantshell in the Clinch River, and while likely not a cause of mass mortality, could reduce fecundity and recruitment in this declining population and threaten the success of reintroductions. Surveillance of *M. clinchi* n. sp. and evaluation of broodstock and their progeny for microsporidia would therefore be prudent.

**Keywords:** *Actinonaias pectorosa*; bivalve; freshwater mussel; histopathology; microsporidia; *Microsporidium clinchi* n. sp.; PCR; TEM; unionid

## 1. Introduction

Worldwide, there are 3 subclasses, 5 orders, and 19 families of freshwater bivalves within the class Bivalvia, with a total of 206 genera and over 1200 species [1,2]. Forty percent of freshwater bivalves are near-threatened, threatened, or extinct [2]. The highest diversity is found in the order Unionida with 797 species [1], nearly half of which are considered near-threatened, threatened, or extinct [2]. In North America, where over 300 species are recognized [3], the situation is even more dire, with two thirds of the mussels listed as threatened or near-threatened [2]. Within the past century, approximately 10% of unionid species in the United States have become extinct [3]. Over a quarter are federally listed as imperiled species [3] and 189 are on the IUCN Red List [4].

Historically, population declines were attributed to commercial over-harvest, habitat destruction, water quality degradation, invasive species, loss of fish hosts for glochidia transformation, and disease [5,6], although strong evidence proving causality is often lacking [7]. More recent population declines have often been “enigmatic” in that mortality with “no clear cause” occurs in an apparently healthy ecosystem [8]. Of the proposed causes of decline, disease has received the least investigative effort [5]. Known pathogens of freshwater mussels include bacteria, fungi, protozoan and metazoan parasites, and viruses [4,9–11]. While these pathogens may cause decreased host fitness, their ability to cause disease and their effect on hosts at the individual and population level remain largely uncharacterized [4]. Parasites with a substantial effect on the host include bucephalid trematodes, which infect the gonad and can result in decreased fecundity and, in high numbers, can render the host sterile [9]. A single viral disease, Lea virus, occurs in the Chinese pearl mussel (*Hyriopsis cumingii*), but disease has only been reported in cultured mussels [12,13].

At this time, no pathogens of freshwater mussels have been definitively linked to mussel declines and mortality events in North America, but investigation of potential pathogens warrants additional attention [8]. Understanding the role of pathogens at the individual and population levels for freshwater mussels, as well as evaluating the potential for disease transmission with translocation efforts, are urgent priorities [3], particularly given the possibility that restoration strategies could inadvertently cause harm to native populations if conducted without sufficient supporting research on parasitism and disease risks [14]. Here, we report on the identification of a novel microsporidian parasite, *Microsporidium clinchi* n. sp., infecting the gonad and gills of wild pheasantshell (*Actinonaias pectorosa*; syn: *Ortmanniana pectorosa*) collected from the Clinch River, USA, and discuss its potential to decrease fecundity and recruitment in this vulnerable population.

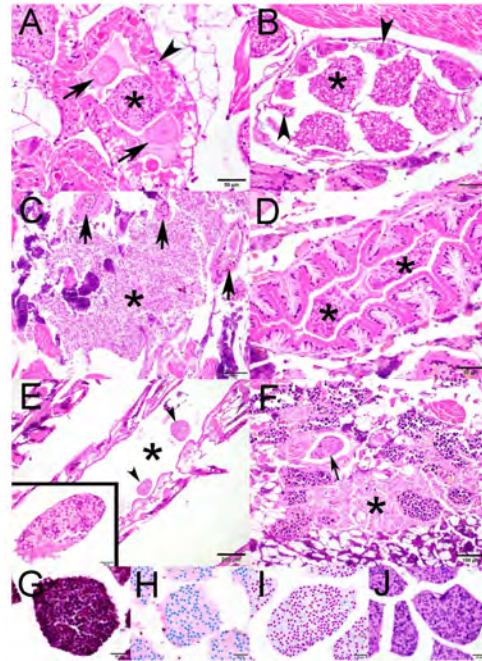
Microsporidia are obligate, intracellular, spore-forming fungal-like parasites that occur worldwide in terrestrial, marine, and freshwater ecosystems. There are more than 1400 species and 200 genera that infect invertebrates and vertebrates, including humans [15]. Their life cycle involves merogony in which proliferation occurs, and sporogony, which results in the production of an infective spore [16]. Transmission can occur vertically with spores passing from an infected host to its progeny, or horizontally by environmental contamination, or by both routes in some species [15]. In freshwater environments, microsporidians are known to affect invertebrates through gonadotropic infections that impact fecundity and have even been associated with catastrophic population declines [17,18]. Here, we describe the histologic and ultrastructural characteristics of a novel microsporidian parasite in freshwater mussels and present the small subunit (SSU) rRNA gene sequence and its closest identity.

## 2. Results

### 2.1. Histopathology

Within the ovary of wild pheasantshell (*A. pectorosa*), round-to-oval microsporidial spores often filled the cytoplasm of mature oocytes that were free in the ovarian acinar lumen and immature oocytes still attached to the acinar wall (Figure 1A,B). Nuclei were often obscured or displaced to the periphery of the cell. Occasionally, microsporidia were free within the ovarian tissue (Figure 1C), especially in mussels with degenerate acini. Microsporidial-infected mature oocytes were also observed within the lumen of ovarian ciliated gonadal ducts (Figure 1D) and the water tube of the gill (Figure 1E). Within the testes of a single animal, spores were present within a cell in the lumen of the ciliated gonadal duct and free within the testes (Figure 1F). Mature spores stained blue with Brown–Brenn while immature spores were stained red (Figure 1G). The proliferative stages were stained blue with Giemsa (Figure 1H). Ziehl–Neelsen staining was variable with spores being stained magenta (Figure 1I). Magenta staining of the spore’s polar cap was not observed with the periodic acid–Schiff (PAS) technique (Figure 1J). There was no associated inflammatory response to the microsporidial-infected cells or free microsporidia in the

ovary, testes, or gills. Microsporidia were not observed histologically in the mantle, foot, digestive gland, intestine, heart, nephridium, pedal ganglion, or nerve (Figure S1).



**Figure 1.** Photomicrographs of the ovary, gill, or testes of wild pheasantshell (*Actinonaias pectorosa*) collected from the Clinch River, USA: (A) an ovarian acinus with oogonia and immature oocytes in the acinar wall (arrowhead), two intraluminal uninfected mature oocytes surrounded by a vitelline membrane (arrows), and a mature oocyte containing numerous intracytoplasmic microsporidia (asterisk). Hematoxylin and eosin (H&E); (B) both developing oocytes (arrowheads) still attached to the acinar wall and mature intraluminal oocytes (asterisk) contain intracytoplasmic microsporidia. H&E; (C) myriad microsporidia (asterisk) are free within the ovarian tissue that contains several degenerate acini (arrows). H&E; (D) microsporidial-infected mature oocytes (asterisks) are present in the lumen of the ciliated gonadal duct. H&E; (E) multiple infected mature oocytes (arrowheads) are observed within the water tube (\*), which is situated between the gill filaments. Inset: higher magnification of microsporidia within the cytoplasm of a mature oocyte. H&E; (F) a microsporidial-infected cell (arrow) is present in a testicular ciliated gonadal duct, and microsporidia are free within the testes (asterisk). H&E; (G) mature spores stain blue while immature spores stain red with a Brown–Brenn; (H) spore nuclei of presporal stages stained blue with Giemsa; (I) spores stained magenta with Ziehl–Neelsen; (J) no staining of the spore’s polar cap is observed with the PAS technique.

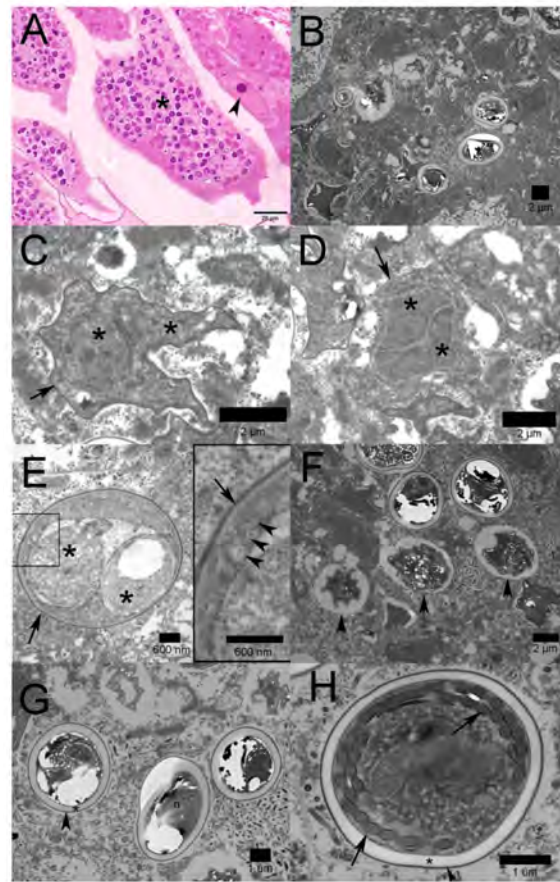
Microsporidia were observed in 65% (17/26) of the examined female pheasantshell (*A. pectorosa*) and in no (0/2) female mucket (*Actinonaias ligamentina*) (Table 1) [19]. Infected female pheasantshell were found at all sites except Frost Ford, with the highest prevalence in the upper and middle Clinch River, 100% prevalence at Artrip (4/4) and Speer’s Ferry (4/4), and 50% prevalence (9/18) in the lower Clinch River. Prevalence in the lower part of the river was 75% (3/4) at Sycamore Island, 25% (1/4) at Wallen Bend, 56% (5/9) at Kyle’s Ford, and 0% (0/1) at Frost Ford. All infected pheasantshell were female except for a single male from Speer’s Ferry. There was no histologic evidence to indicate this individual was a hermaphrodite, but only a single slide of gonad was examined, and we cannot rule out this possibility. Our collection ratio was slightly skewed towards females (28/41) but was skewed towards males in mucket (8/10). Of the 27 mussels for which health status was determined (Table S1), 12 were infected with the microsporidium (8 healthy and 4 moribund) and 19 were uninfected (11 healthy and 4 moribund). There was no statistical association between infection status and health status (Fisher’s exact  $p = 1.000$ ), and this result did not change when the analysis was restricted to females.

**Table 1.** Number of freshwater mussels collected from the Clinch River, USA, infected with *Microsporidium clinchi* n. sp. by state, collection location and date, and species. NA = not applicable.

State	Collection Location	Collection Date	Number of Males (M), Females (F), Undetermined (U)	Infected <i>A. pectorosa</i>	Prevalence in Female <i>A. pectorosa</i>	Infected <i>A. ligamentina</i>
VA	Artrip	26 September 2018	2M 1F	1/3	100% (4/4)	NA
		24 October 2018	0M 3F	3/3		NA
	Speer's Ferry	26 September 2018	1M 2F	3/3	100% (4/4)	NA
		24 October 2018	2M 2F 1U	2/4		0/1
	Sycamore Island	16 August 2018	3M 1F	1/2	75% (3/4)	0/2
		26 September 2018	1M 1F	0/2		NA
TN	Wallen Bend	25 October 2018	3M 2F	2/4		0/1
		16 August 2018	1M 3F	1/2	25% (1/4)	0/2
	Kyle's Ford	26 September 2018	1M 1F	0/2		NA
		16 August 2018	1M 3F	1/2	56% (5/9)	0/2
	Frost Ford	26 September 2018	3M 2F	1/5		NA
		25 October 2018	0M 6F 1U	3/7		NA
Totals		23 August 2018	3M 1F	0/2	0% (0/1)	0/2
			21M 28F 2U	18/41	65% (17/26)	0/10

## 2.2. Transmission Electron Microscopy

A single sample of formalin-fixed paraffin-embedded tissue was available for evaluation; thus, some ultrastructural characteristics could not be confirmed. On a semi-thin section of the ovary of a wild pheasantshell (*A. pectorosa*), the cytoplasm of intraluminal oocytes is filled with various microsporidial developmental stages (Figure 2A). Transmission electron microscopy (TEM) shows representations of the proliferative and sporulation phases (Figure 2B). The proliferative stage begins with merogony, where cell fission occurs. Meronts observed in the cytoplasm of the oocytes had an electron dense plasma membrane and diplokaryotic nuclei (Figure 2C). As described by Vávra et al. [20], parasites in late merogony have “patches of electron-dense material” that occur on the plasma membrane, and as the cell enters sporogony, cisternae of rough endoplasmic reticulum (ER) accumulate concentrically around the nucleus. Late meronts/early sporonts exhibited a surface coat with concentric layers of electron-dense and electron-lucent material that likely represents layers of rough ER (Figure 2D). During sporulation, the sporonts divided into sporoblasts that had a granular cytoplasm with stacks of ER and golgi apparatus, and early polar filaments surrounded by an electron-dense surface coat that will become the exospore (Figure 2E). Late sporoblasts had an electron-dense surface coat (Figure 2F). Mature spores measured  $4.6 \pm 0.65 \mu\text{m}$  (range = 3.6–5.5  $\mu\text{m}$ ) long by  $3.7 \pm 0.33 \mu\text{m}$  (range = 3.25–4.29  $\mu\text{m}$ ) wide ( $n = 9$ ). Fresh spores were not available for measurements, and it should be noted that tissue processing that included dehydration with ethanol likely resulted in spore shrinkage, and actual spore size may be larger than what is reported. Due to sectioning artifacts, it could not be determined whether most spores were monokaryotic or diplokaryotic, and posterior vacuoles were not visualized. Spores had a thick electron-lucent endospore, a thin electron-dense exospore, and nuclei (Figure 2G,H). The spore wall measured  $0.35 \pm 0.04 \mu\text{m}$  (range = 0.29–0.41  $\mu\text{m}$ ;  $n = 9$ ). Due to the limited number of spores available in the sections, it was not possible to state a definitive range of polar filament coils.



**Figure 2.** A semi-thin section and transmission electron micrographs of the ovary of a wild pheasantshell (*A. pectorosa*) collected from the Clinch River, USA: (A) Semi-thin section stained with toluidine blue of an ovarian acinus with intraluminal mature oocytes containing numerous intracytoplasmic microsporidia (asterisk) in various stages of development and a developing oocyte (arrowhead) on the acinar wall; (B) various stages of developing microsporidia within the cytoplasm of an oocyte; (C) meront with electron-dense plasma membrane (arrow) and diplokaryotic nuclei (asterisks) is present in the cytoplasm of an oocyte; (D) a diplokaryotic (asterisks) late meront/early sporant with a surface coat of concentric layers of electron-dense and electron-lucent material, likely representing layers of rough endoplasmic reticulum (arrow); (E) diplokaryotic sporoblast (asterisks) with granular cytoplasm surrounded by an electron-dense surface coat (arrow) that will become the exospore. Inset: higher magnification showing early polar filaments (arrowheads) and electron-dense surface coat (arrow); (F) late sporoblasts (arrowheads) with an electron-dense surface coat; (G) mature spores with nucleus (n), a thick electron-lucent endospore (asterisk), and thin electron-dense exospore (arrowhead); (H) mature spore with 13–14 polar filament coils (arrows), a thick electron-lucent endospore (asterisk), and thin electron-dense exospore (arrowhead).

### 2.3. Molecular Identification

A 1333 bp sequence of small subunit (SSU) rRNA for *Microsporidium clinchi* n. sp. (GenBank accession number: OL117026) did not share a high degree of similarity with any entries in GenBank, although some similarity was found with several microsporidians known to infect a variety of freshwater invertebrates. The BLAST results with the highest similarities were as follows: *Pseudonosema cristatellae* (AF484694.1; 86.36%; e-value = 0; Host: the freshwater bryozoan *Cristatella mucedo*), *Microsporidia* sp. (MT622752.1; 85.79%; e-value = 0; Host: the freshwater dipteran *Kiefferulus barbatitarsis*), and *Janacekia* sp. (MW537817.1; 85.79%; e-value = 0; Host: the freshwater dipteran *Kiefferulus tainanus*). Other BLAST results sharing lesser similarities were microsporidians of invertebrates, most of which were aquatic.

#### 2.4. Description

Microspora Sprague, 1977

Microsporea Delphy, 1963

*Microsporidium clinchi* n. sp. (Figure 2)

Diagnosis: Histologic examination shows round-to-ovoid spores that partially or completely fill the cytoplasm of immature and mature oocytes. With transmission electron microscopy, mature spores measured 4.6 µm long and 3.7 µm wide with a 0.35 µm thick spore wall.

##### 2.4.1. Taxonomic Summary

Type Host: *A. pectorosa* (Pheasantshell Mussel)

Site of Infection: Gonad (Primarily Ovary)

Type Locality: Clinch River, VA, USA (35.86° N, 84.53° W)

Prevalence: 17 of 26 females.

Specimens deposited: Hapantotype slides of stained sections of gonadal tissue were deposited in the Smithsonian National Museum of Natural History (Washington, DC, USA) under USNM 1660909-1660911. Extracted DNA was also submitted under USNM 1660909.

Etymology: This species name is in regard to collection location.

DNA sequences: A 1333 bp sequence of SSU rRNA was submitted to GenBank under accession OL117026.

##### 2.4.2. Remarks

We classified the novel, gonadotropic microsporidium that infects pheasantshell mussels in the Clinch River as a *Microsporidium*, a genus representing a collection of microsporidian species that require more work to determine a more appropriate taxonomic placement [21,22]. At first glance, a suitable genus designation might be within *Steinhausia*, a group with spherical-to-ovoid spores known to cause intracytoplasmic infections in the cells of mollusks, and the only genus known to infect bivalve oocytes [23]. The following four species have been described in this genus: *S. mytilovum* and *S. ovicola* infect the ovaries of marine bivalves (Bivalvia), *S. brachynema* infects various tissues of an aquatic snail (Gastropoda), and *S. spraguei* infects the kidney of ovalbone cuttlefish (Cephalopoda) [24,25]. Furthermore, unnamed *Steinhausia* and *Steinhausia*-like infections in bivalves have been identified in the ovary of Baltic clam (*Macoma balthica*) [26], the clam *Venerupis corrugata* (synonym: *Venerupis pullastra*) [27], Sydney rock oyster (*Saccostrea commercialis*) [28], the common cockle (*Cerastoderma edule*) [29,30], and oysters (*Crassostrea gasar*) in Brazil [31]. Both morphological and genetic data suggest that *M. clinchi* is a novel species. Morphologically, the mature spores of *M. clinchi* are quite different from other oocytes infecting microsporidians of mollusks. The spores of *M. clinchi* (4.6 µm long and 3.7 µm wide with a 0.35 µm thick wall) are much larger and have a thicker spore wall than either *S. mytilovum* (1.6 to 1.8 µm long; 125 nm thick wall) [32] or *S. ovicola* (2 µm in diameter) [33].

*Microsporidium clinchi* n. sp. shares some general characteristics with the described *Steinhausia* spp., in that the new species causes a gonadal infection in a mussel with round-to-oval spores that develop in the cytoplasm. However, there are inconsistent characteristics within *Steinhausia* that, when combined with an absolute lack of molecular data, make it difficult to place *M. clinchi* n. sp. in the genus at this time. For example, a “honeycomb middle layer” associated with the polar filament has been observed in species assigned to *Steinhausia* [24,34]. However, this feature was not observed with *M. clinchi* n. sp. and also was not observed from study of *S. mytilovum*, the type species for the genus [32]. Furthermore, Sagrista et al. [32] also suggested that *S. brachynema* has characteristics, including only possessing one nucleus as well as the honeycombed feature, which are not observed in other *Steinhausia* spp., and that this species likely belongs to another genus. Another inconsistency among members of *Steinhausia* involves the thickness of the spore wall. Sprague et al. [24] noted that spores for *Steinhausia* spp. had a thin membrane-like wall. The spore wall for *M. clinchi* n. sp. appears relatively thick. A report of *S. mytilovum*

from mussels in Brazil [23] showed thicker spore walls than other published electron micrographs of *S. mytilovum* from Europe [32]. However, given the parasites evaluated in these two reports were not compared molecularly and were from different hosts on opposite sides of the Earth, it would be reasonable to think that they may not have actually been the same species. Furthermore, the oocytes infecting *Steinhausia* spp. are known to produce sporocysts adjacent to the host cell nucleus, resulting in low-level infections that presumably allow the host egg to mature normally [32]. While *M. clinchi* n. sp. develops within the cytoplasm of the oocyte, it does not have a clear point of origin near the nucleus, and proliferation often fills the cytoplasm of the oocyte. It should be noted, however, that not all ultrastructural features could be identified due to sample preservation and limited sample size. The sequence deposited in GenBank for *M. clinchi* n. sp. is the first sequence available for any oocyte infecting microsporidian associated with mollusks. Future work utilizing both morphological and molecular methods to evaluate *Steinhausia* spp. would be valuable in determining whether all these mollusk-infecting parasites indeed belong to the same genus.

### 3. Discussion

The upper Clinch River suffered massive declines in unionid diversity and population density in the 1960s–1980s, and a “zone of decline” remains in the middle river, characterized by low mussel diversity and density [35]. In the lower river, most locations have maintained large proportions of their historical density and are characterized by better water quality than sites upstream in the watershed [35]. However, a mass mortality event occurred in the lower Clinch River from 2016–2019 and caused an 85.4% loss in the pheasantshell population [36]. The highest prevalences of *M. clinchi* n. sp. occurred in the upper and middle Clinch River, where mass mortality was not observed, while prevalence was lowest at the site of the mass mortality event in the lower river. For this reason, *M. clinchi* n. sp. does not appear to be a primary cause of the ongoing mortality event. However, it may play some role in the cumulative stress experienced by populations in the lower river and may also be contributing to the ongoing issues of low population density and limited recruitment observed in upper river populations.

One aspect of *M. clinchi* n. sp. infection that warrants further study is the role of stress and immunosuppression in the pathogenesis. In fish, otherwise healthy individuals can become infected with microsporidians, while immunosuppression has been shown to produce more severe infections [37,38]. It would therefore be important to determine whether stressors are associated with the intense infections observed in pheasantshell from the Clinch River; if they can be identified, mitigation strategies could be developed with the potential to improve reproductive rates for this declining species.

The observed presence of *M. clinchi* n. sp. at most sites throughout the Clinch River is concerning, as the robust populations of the lower river are the broodstock sources for restoration efforts involving more than a dozen federally endangered mussels in the Upper Tennessee River Basin. The reason for concern is that not only can microsporidial spores persist in the environment for years [16], but they also have the potential to disrupt populations through decreasing fecundity and recruitment [39]. In the pheasantshell mussels observed in this study, ovarian tissue was heavily infected by *M. clinchi* n. sp. Furthermore, spores were observed within the cytoplasm of infected oocytes, suggesting that transovarian vertical transmission is possible. Other loose microsporidian spores present in the ovary also suggest the potential for horizontal transmission. The ability for microsporidians to spread via both horizontal and vertical routes has been previously documented [40]. In general, horizontally transmitted microsporidians tend to be associated with more virulent infections that produce high parasite burdens in the host, while vertically transmitted microsporidians tend to be less pathogenic but are known to distort the sex ratios through feminization and/or killing of male hosts [40]. *Steinhausia* infections of marine bivalve oocytes have been observed to be slight, still allowing typical development of an infected egg [32]. However, with *M. clinchi* n. sp. infected ovaries, microsporidia filled much

of the oocyte cytoplasm, leaving questions regarding oocyte viability and the likelihood of subsequent vertical transmission. The intracytoplasmic location of the microsporidia, however, does allow for avoidance of the host immune response [17]. Further complicating any understanding regarding the transmission of *M. clinchi* n. sp. is that microsporidians can have simple or complex lifecycles involving other aquatic invertebrates, as well as alternating routes of transmission [40]. The development of a qPCR assay to search for this microsporidium in other mussel species, invertebrate hosts, and environmental samples will be a critical first step in learning more about this important pathogen of freshwater mussels. Furthermore, evaluation of ovary from a single mussel with poor preservation did not allow for the elucidation of all of the ultrastructural characteristics of *M. clinchi* n. sp. Future work could include the evaluation of glutaraldehyde-preserved tissues from multiple specimens.

The inadvertent spread of this parasite warrants consideration due to the high level of environmental persistence associated with microsporidians as well as the threats to mussel reproduction, including the potential for transovarian vertical transmission, presented by *M. clinchi* n. sp. Due to these risks, it would be beneficial to evaluate mussels from the Clinch River that are used in propagation and restoration efforts for the presence of this parasite. Furthermore, understanding the geographic distribution, potential seasonality, effects of stress on recrudescence, and lethal or sub-lethal effects of *M. clinchi* n. sp. on pheasantshell and other species would provide important information to managers as they assess the risks presented by this parasite to Clinch River mussel populations and associated restoration efforts.

#### 4. Materials and Methods

##### 4.1. Experimental Design and Field Sampling

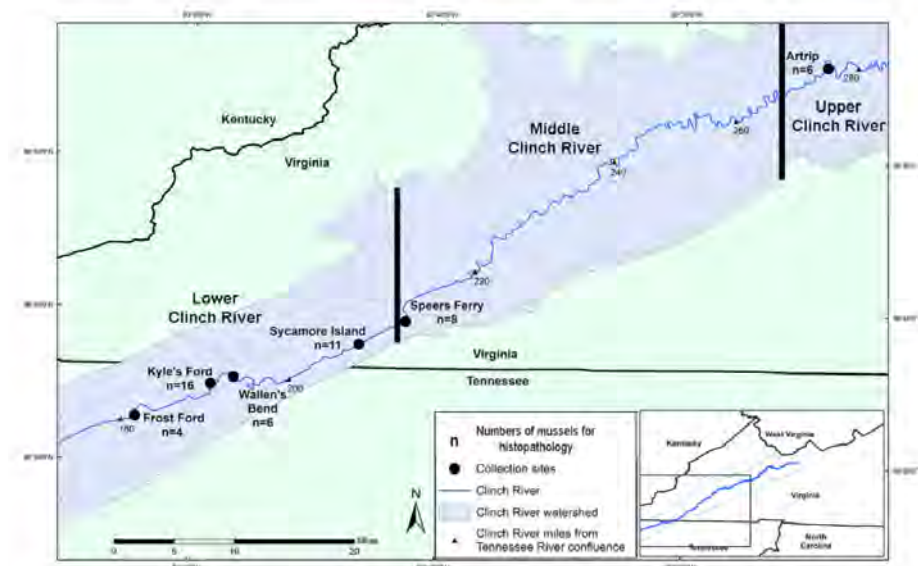
During August, September, and October of 2018, we sampled adult pheasantshell (*A. pectorosa*) and mucket (*A. ligamentina*) from 6 sites in the Clinch River, VA and TN, USA (Figure 3) as part of an epidemiologic survey investigating an ongoing freshwater mussel mass mortality event as described in Richard et al. [41,42] and Leis et al. [43]. Mussel health was recorded as “healthy,” “moribund”, or indeterminate (Supplementary Table S1) [19]. Mortality occurring in the lower Clinch River and the middle and upper Clinch River were considered control sites. Pheasantshell was the primary species experiencing ongoing mortality; thus, most samples examined were from this species. A few mucket were collected for comparison to pheasantshell to determine whether potential etiologic agents contributing to mortality were also observed in closely related species not experiencing morbidity or mortality. While non-lethally collecting hemolymph samples from the anterior adductor muscle for use in viral and bacteriological assays, we selected 41 *A. pectorosa* and 10 *A. ligamentina* to be sacrificed for histologic evaluation and molecular assays to identify potential pathogens. These mussels were wrapped in damp paper towels, individually sealed in plastic bags, and placed in a cooler on ice.

##### 4.2. Tissue Processing

Mussels were shipped on ice overnight to the La Crosse Fish Health Center (Onalaska, WI) and transferred to the U.S. Geological Survey (USGS) Upper Midwest Environmental Sciences Center (La Crosse, WI, USA) for purging. Mussels were placed in a holding tank with flow-through water and aeration at 12 °C to purge for 24–72 h. The body mass was dissected along a dorsal–ventral plane (through the pericardium, digestive gland, and foot) and the posterior portion was placed in 10% neutral buffered formalin (NBF) for at least 24 h for histological examination. The anterior portion was frozen at –80 °C for molecular analyses. Formalin-fixed tissues were washed in water and transferred from 50 to 70% ethanol and sent to the USGS National Wildlife Health Center (Madison, WI, USA). A cross-section of the fixed mussel including gonad was placed in a tissue cassette in 10% NBF. Fixed tissues were processed routinely, sectioned at approximately 5 µm, and stained with hematoxylin and eosin at the Wisconsin Veterinary Diagnostic Laboratory



(WVDL; Madison, WI, USA). Slides were stained using a Leica AutoStainer XL (Leica Microsystems, Wetzlar, Germany). Slides were deparaffinized in xylene 1× for 3 min and 2× for 1 min. Tissues were hydrated in 100% ethyl alcohol (EtOH) 2× for 30 s, 1× for 1 min, in 95% EtOH for 1 min, and rinsed in reverse osmosis/deionized water (RO/DI H<sub>2</sub>O) for 1 min. Slides were stained with Surgipath SelecTech Hematoxylin 560 (Leica Microsystems, Wetzlar, Germany) for 1.5 min and rinsed with RO/DI H<sub>2</sub>O for 5 min. Tissues were differentiated with Surgipath SelecTech Define for 1.5 min and rinsed with RO/DI H<sub>2</sub>O for 5 min. Slides were placed in Surgipath SelecTech Blue Buffer 8 for 45 s and rinsed in RO/DI H<sub>2</sub>O for 2 min. Slides were placed in 95% EtOH for 45 s and counterstained with Surgipath SelecTech Eosin Y 515 for 45 s. Tissues were dehydrated in 100% EtOH 3× for 1 min and cleared with xylene 2× for 1 min. To visualize microsporidial spores, select tissues were stained with Gram (Brown–Brenn), Giemsa, Ziehl–Neelsen stains, and the periodic acid–Schiff (PAS) technique at WVDL, and examined by light microscopy using an Olympus BX43 microscope.



**Figure 3.** Map of collection locations in the Clinch River, USA. Black bars represent approximate boundaries dividing the upper, middle, and lower sections of the Clinch River referenced in the Discussion.

#### 4.3. Transmission Electron Microscopy

A paraffin block from a microsporidial-infected pheasantshell from Wallen's Bend was submitted to the Electron Microscope Core at the University of Wisconsin's School of Medicine and Public Health (Madison, WI, USA) for processing for transmission electron microscopy. Target areas were removed from formalin-fixed paraffin-embedded blocks. Samples were de-paraffinized using histological-grade xylene (4 × 10 min, room temperature (RT)) and rehydrated in an ethanol series (100%, 95%, 90%, 80%, 70%, 50% 35%) for 10 min each at RT, and placed in phosphate buffer (PB). Samples were immersion fixed in 2.5% glutaraldehyde, 2.0% paraformaldehyde in 0.1 M PB for 2 h at RT. The primary fixed samples were rinsed 5 × 5 min in PB, and post-fixed in 1% osmium tetroxide in 0.1 M PB for 1 h at RT, and rinsed in PB as before.

Dehydration was performed in a graded ethanol series (35%, 50%, 70%, 80%, 90% for 10 min each step, 95% for 20 min, 100% for 3 × 10 min) at RT and then transitioned in acetone 2 × 7 min at RT. Fully dehydrated samples were infiltrated in increasing concentrations of PolyBed 812 (Polysciences Inc.; Warrington, PA, USA) and acetone mixtures in the following order (Table 2).

**Table 2.** Fully dehydrated samples were infiltrated in increasing concentrations of PolyBed 812 and acetone mixtures in orders.

Orders	PolyBed 812	Acetone	Time	Temp.
1	25%	75%	60 min	RT
2	50%	50%	60 min	RT
3	75%	25%	Overnight	RT
4	100%	0%	2 × 45 min	60 °C

Embedding and polymerization took place in fresh PolyBed 812 for 24 h at 60 °C.

The samples were sectioned on a Leica EM UC6 ultramicrotome at 100 nm. Sections were collected on formvar coated 2 × 1 mm slot Cu grids (EMS; Hatfield, PA, USA), and post-stained with uranyl acetate and lead citrate. The sectioned samples were viewed at 80 kV on a Philips CM120 transmission electron microscope, equipped with an AMT BioSprint12 side-mount digital camera (AMT Imaging, Woburn, MA, USA). Semi-thin sections were stained with Toluidine blue and examined by light microscopy.

#### 4.4. DNA Extraction and PCR

Samples of frozen ovary from mussels that were histologically identified as infected with microsporidians were placed in a microcentrifuge tube. Microsporidian DNA was extracted using a DNeasy Tissue Kit (Qiagen; Germantown, MD, USA). A portion of the SSU rRNA gene was amplified using primers VF1 and 1492R [37], and the resulting PCR products were Sanger sequenced by Eton Biosciences (Union, NJ, USA). The sequences were then edited in Geneious 2021.1.1 and queried against the GenBank database using the BLAST algorithm [44] to identify similar sequences.

**Supplementary Materials:** The following are available online at <https://www.mdpi.com/article/10.3390/parasitologia2010001/s1>, Table S1: Freshwater mussels collected from the Clinch River, USA by accession number, collection date and location, species, health status, sex, and microsporidia infection status, Figure S1: Photomicrographs stained with hematoxylin and eosin (H&E) of uninfected organs from microsporidial-infected wild pheasantshell (*Actinonaias pectorosa*) collected from the Clinch River, USA. (a) Mantle with a wall composed of loose connective tissue and muscle fibers surrounded on either side by epithelium; (b) Foot with plicated integument and central musculature; (c) Digestive gland showing digestive diverticulum with vesiculated digestive cells and basally located basophilic nuclei; (d) Intestine showing ciliated epithelium, a lamina propria and surrounding adipose tissue; (e) Heart encircling the intestine. Cardiac myofibers are obscured by abundant basophilic mineral concretions; (f) Nephridium showing columnar epithelium with intracytoplasmic brown granules and basally located basophilic nuclei; (g) Pedal ganglion showing neurons and nerve fibers; (h) Nerve showing nerve fibers surrounded by perineurium.

**Author Contributions:** Conceptualization, S.K., E.M.L., J.C.R., R.E.A., J.G.P., T.L.G. and D.L.W.; data curation, S.K., E.M.L. and J.C.R.; formal analysis, S.K., E.M.L., J.C.R. and R.C.; funding acquisition, J.C.R., T.L.G. and D.L.W.; investigation, S.K., E.M.L., J.C.R., R.E.A. and J.G.P.; methodology, S.K., E.M.L., J.C.R., R.C., R.E.A., J.G.P., T.L.G. and D.L.W.; project administration, S.K. and E.M.L.; resources, S.K., E.M.L. and D.L.W.; supervision, D.L.W.; validation, S.K., E.M.L., J.C.R. and R.C.; visualization, S.K. and E.M.L.; writing—original draft, S.K., E.M.L. and J.C.R.; writing—review and editing, S.K., E.M.L., J.C.R., R.C., R.E.A., J.G.P., T.L.G. and D.L.W. All authors have read and agreed to the published version of the manuscript.

**Funding:** This research was funded by the U.S. Fish and Wildlife Service, grant number F20AC10617 and the U.S. Geological Survey, Ecosystem Mission Area, along with support from the University of Wisconsin-Madison.

**Institutional Review Board Statement:** Ethical review and approval were waived for this study, due to work with invertebrates.

**Informed Consent Statement:** Not applicable.

**Data Availability Statement:** Data for this study are available at <https://doi.org/10.5066/P9U4RYE1> (accessed on 27 October 2021) [19].

**Acknowledgments:** We thank Tim Lane, Brian Watson, Sarah Colletti, Tiffany Leach, Brett Ostby, and Caitlin Carey for assistance with field work, John Fisher (National Conservation Training Center) for assistance finding reference materials, and Randall Massey for TEM technical assistance.

**Conflicts of Interest:** The authors declare no conflict of interest. The use of trade, firm or product names is for descriptive purposes only and does not imply endorsement by the U.S. Government. The findings and conclusions in this article are those of the authors and the U.S. Geological Survey and do not necessarily represent the views of the U.S. Fish and Wildlife Service.

## References

- Bogan, A.E. Global Diversity of Freshwater Mussels (Mollusca, Bivalvia) in Freshwater. *Hydrobiologia* **2008**, *595*, 139–147. [CrossRef]
- Lopes-Lima, M.; Burlakova, L.E.; Karatayev, A.Y.; Mehler, K.; Seddon, M.; Sousa, R. Conservation of Freshwater Bivalves at the Global Scale: Diversity, Threats and Research Needs. *Hydrobiologia* **2018**, *810*, 1–14. [CrossRef]
- Haag, W.R.; Williams, J.D. Biodiversity on the Brink: An Assessment of Conservation Strategies for North American Freshwater Mussels. *Hydrobiologia* **2014**, *735*, 45–60. [CrossRef]
- Carella, F.; Villari, G.; Maio, N.; De Vico, G. Disease and Disorders of Freshwater Unionid Mussels: A Brief Overview of Recent Studies. *Front. Physiol.* **2016**, *7*, 489. [CrossRef]
- Haag, W.R. The Decline of the North American Mussel Fauna: Chronology and Causes. In *North American Freshwater Mussels: Natural History, Ecology, and Conservation*; Cambridge University Press: Cambridge, UK, 2012; pp. 316–390.
- Starliper, C.E. Pathogens and Diseases of Freshwater Mussels in the United States: Studies on Bacterial Transmission and Depuration. Bridging America and Russia with Shared Perspectives on Aquatic Animal Health. In Proceedings of the Third Bilateral Conference between Russia and the United States, Shepherdstown, WV, USA, 12–20 July 2009; Cipriano, R.C., Bruckner, A.W., Shchelkunov, I.S., Eds.; Khaled bin Sultan Living Oceans Foundation: Landover, MD, USA, 2011; pp. 47–55.
- Downing, J.A.; Van Meter, P.; Woolnough, D.A. Suspects and Evidence: A Review of the Causes of Extirpation and Decline in Freshwater Mussels. *Anim. Biodivers. Conserv.* **2010**, *33.2*, 151–185.
- Haag, W.R. Reassessing Enigmatic Mussel Declines in the United States. *Freshw. Mollusk Biol. Conserv.* **2019**, *22*, 43–60. [CrossRef]
- Grizzle, J.M.; Brunner, C.J. Infectious Diseases of Freshwater Mussels and Other Freshwater Bivalve Mollusks. *Rev. Fish. Sci.* **2009**, *17*, 425–467. [CrossRef]
- McElwain, A. Are Parasites and Diseases Contributing to the Decline of Freshwater Mussels (Bivalvia, Unionida)? *Freshw. Mollusk Biol. Conserv.* **2019**, *22*, 85–89. [CrossRef]
- McElwain, A.; Warren, M.B.; Pereira, F.B.; Ksepka, S.P.; Bullard, S.A. Pathobiology and First Report of Larval Nematodes (*Ascaridomorpha* sp.) Infecting Freshwater Mussels *Villosa nebulosa* (Unionidae), Including an Inventory of Nematode Infections in Freshwater and Marine Bivalves. *Int. J. Parasitol. Parasites Wildl.* **2019**, *10*, 41–58. [CrossRef]
- Zhang, G.; Wu, X.; Li, J. Advances of the Studies on Diseases of *Hyriopsis cumingii* and Its Control. *J. Shanghai Fish.* **2005**, *14*, 313–318. (In Chinese)
- Lei, Z.; Tiao-Yi, X.; Jie, H.; Liang-Ying, D.; Xiao-Yan, L. Histopathological Examination of Bivalve Mussel *Hyriopsis cumingii* Lea Artificially Infected by Virus. *Acta Hydrobiol. Sin.* **2011**, *35*, 666–671. [CrossRef]
- Brian, J.I.; Ollard, I.S.; Aldridge, D.C. Don't Move a Mussel? Parasite and Disease Risk in Conservation Action. *Conserv. Lett.* **2021**, *14*, e12799. [CrossRef]
- Han, B.; Takvorian, P.M.; Weiss, L.M. Invasion of Host Cells by Microsporidia. *Front. Microbiol.* **2020**, *11*, 172. [CrossRef] [PubMed]
- Garcia, L.S. Laboratory Identification of the Microsporidia. *J. Clin. Microbiol.* **2002**, *40*, 1892–1901. [CrossRef]
- Stentiford, G.D.; Dunn, A.M. Microsporidia in Aquatic Invertebrates. In *Microsporidia: Pathogens of Opportunity*; Weiss, L.M., Becnel, J.J., Eds.; John Wiley & Sons, Inc.: Chichester, UK, 2014; pp. 579–604.
- Kohler, S.L.; Wiley, M.J. Parasite-Induced Collapse of Populations of a Dominant Grazer in Michigan Streams. *Oikos* **1992**, *65*, 443–449. [CrossRef]
- Knowles, S.; Leis, E.M.; Richard, J.C.; Cole, R.; Agbalog, R.E.; Putnam, J.G.; Goldberg, T.L.; Waller, D.L. A Novel Gonadotropic Microsporidian Parasite (*Microsporidium clinchi* n. sp.) Infecting a Declining Population of Pheasantshell Mussels (Actinonaias pectorosa) (Unionidae) from the Clinch River, USA: U.S. Geological Survey Data Release. Available online: <https://doi.org/10.5066/P9U4RYE1> (accessed on 27 October 2021).
- Vávra, J.; Ronny Larsson, J.I. Structure of Microsporidia. In *Microsporidia: Pathogens of Opportunity*; Weiss, L.M., Becnel, J.J., Eds.; John Wiley & Sons, Inc.: Chichester, UK, 2014; pp. 1–70.
- Hoffman, G.L.; Williams, E.H. Subkingdom Protozoa (Kingdom Protista). In *Parasites of North American Freshwater Fishes*; Cornell University Press: Ithaca, NY, USA, 1999; pp. 21–91.
- Sprague, V.; Becnel, J.J.; Hazard, E.I. Taxonomy of Phylum Microspora. *Crit. Rev. Microbiol.* **1992**, *18*, 285–395. [CrossRef]
- Matos, E.; Matos, P.; Azevedo, C. Observations on the Intracytoplasmic Microsporidian *Steinhausia mytilovum*, a Parasite of Mussel (*Mytella guyanensis*) Oocytes from the Amazon River Estuary. *J. Morphol. Sci.* **2005**, *22*, 183–186.

24. Sprague, V.; Ormières, R.; Manier, J.F. Creation of a New Genus and a New Family in the Microsporida. *J. Invertebr. Pathol.* **1972**, *20*, 228–231. [[CrossRef](#)]
25. Kalavati, C.; Narasimhamurti, C.C. *Steinhausia spraguei* n. sp. a Microsporidian Parasite of the Excretory Cells Found in the Fluid from Renal Appendages of *Sepia elliptica*. *Rivista Parassit* **1977**, *38*, 271–275.
26. Farley, C.A. Neoplasms in Estuarine Mollusks and Approaches to Ascertain Causes. *Ann. N. Y. Acad. Sci.* **1977**, *298*, 225–232. [[CrossRef](#)]
27. Villalba, A.; Carballal, M.J.; López, M.C. Pathologic Conditions of Three Carpet Shell Clam Species of Galicia (NW. of Spain). In Proceedings of the Proceedings of World Aquaculture '93—From discovery to commercialization, Torremolinos, Spain, 26–28 May 1993; Carrillo, M., Ed.; European Aquaculture Society: Oostende, Belgium, 1993; p. 85.
28. Anderson, T.; Hine, P.; Lester, R. A *Steinhausia*-like Infection in the Ovocytes of Sydney Rock Oysters *Saccostrea commercialis*. *Dis. Aquat. Organ.* **1995**, *22*, 143–146. [[CrossRef](#)]
29. Carballal, M.J.; Iglesias, D.; Santamarina, J.; Ferro-Soto, B.; Villalba, A. Parasites and Pathologic Conditions of the Cockle *Cerastoderma edule* Populations of the Coast of Galicia (NW Spain). *J. Invertebr. Pathol.* **2001**, *78*, 87–97. [[CrossRef](#)] [[PubMed](#)]
30. Comtet, T.; Garcia, C.; Le Coguic, Y.; Joly, J. Infection of the Cockle *Cerastoderma edule* in the Baie Des Veys (France) by the Microsporidian Parasite *Steinhausia* sp. *Dis. Aquat. Organ.* **2003**, *57*, 135–139. [[CrossRef](#)] [[PubMed](#)]
31. Silva, P.M.D.; Scardua, M.P.; Vieira, C.B.; Alves, A.C.; Dungan, C.F. Survey of Pathologies in *Crassostrea gasar* (Adanson, 1757) Oysters from Cultured and Wild Populations in the São Francisco Estuary, Sergipe, Northeast Brazil. *J. Shellfish Res.* **2015**, *34*, 289–296. [[CrossRef](#)]
32. Sagristà, E.; Bozzo, M.G.; Bigas, M.; Poquet, M.; Durfort, M. Developmental Cycle and Ultrastructure of *Steinhausia mytilovum*, a Microsporidian Parasite of Oocytes of the Mussel, *Mytilus galloprovincialis* (Mollusca, Bivalvia). *Eur. J. Protistol.* **1998**, *34*, 58–68. [[CrossRef](#)]
33. Léger, L.; Hollande, A. Sur Un Nouveau Protiste À Facies De Chytridiopsis, Parasite Des Ovules De L'huître. *CR Séances Soc. Biol. Paris* **1917**, *80*, 61–64.
34. Cunningham, A.A.; Daszak, P. Extinction of a Species of Land Snail Due to Infection with a Microsporidian Parasite. *Conserv. Biol.* **1998**, *12*, 1139–1141. [[CrossRef](#)]
35. Cope, W.G.; Bergeron, C.M.; Archambault, J.M.; Jones, J.W.; Beaty, B.; Lazaro, P.R.; Shea, D.; Callihan, J.L.; Rogers, J.J. Understanding the Influence of Multiple Pollutant Stressors on the Decline of Freshwater Mussels in a Biodiversity Hotspot. *Sci. Total Environ.* **2021**, *773*, 144757. [[CrossRef](#)]
36. Richard, J. Clinch River Mussel Die-Off. *Ellipsaria* **2018**, *20*, 1–3.
37. Sanders, J.; Lawrence, C.; Nichols, D.; Brubaker, J.; Peterson, T.; Murray, K.; Kent, M. *Pleistophora hyphessobryconis* (Microsporidia) Infecting Zebrafish *Danio rerio* in Research Facilities. *Dis. Aquat. Organ.* **2010**, *91*, 47–56. [[CrossRef](#)]
38. Sanders, J.L.; Watral, V.; Kent, M.L. Microsporidiosis in Zebrafish Research Facilities. *ILAR J.* **2012**, *53*, 106–113. [[CrossRef](#)]
39. Ebert, D. The Ecological Interactions Between a Microsporidian Parasite and Its Host *Daphnia magna*. *J. Anim. Ecol.* **1995**, *64*, 361–369. [[CrossRef](#)]
40. Dunn, A.M.; Smith, J.E. Microsporidian Life Cycles and Diversity: The Relationship between Virulence and Transmission. *Microbes Infect.* **2001**, *3*, 381–388. [[CrossRef](#)]
41. Richard, J.C.; Leis, E.; Dunn, C.D.; Agbalog, R.; Waller, D.; Knowles, S.; Putnam, J.; Goldberg, T.L. Mass Mortality in Freshwater Mussels (*Actinonaias pectorosa*) in the Clinch River, USA, Linked to a Novel Densovirus. *Sci. Rep.* **2020**, *10*, 14498. [[CrossRef](#)]
42. Richard, J.C.; Campbell, L.J.; Leis, E.M.; Agbalog, R.E.; Dunn, C.D.; Waller, D.L.; Knowles, S.; Putnam, J.G.; Goldberg, T.L. Mussel Mass Mortality and the Microbiome: Evidence for Shifts in the Bacterial Microbiome of a Declining Freshwater Bivalve. *Microorganisms* **2021**, *9*, 1976. [[CrossRef](#)] [[PubMed](#)]
43. Leis, E.; Erickson, S.; Waller, D.; Richard, J.; Goldberg, T. A Comparison of Bacteria Cultured from Unionid Mussel Hemolymph Between Stable Populations in the Upper Mississippi River Basin and Populations Affected by a Mortality Event in the Clinch River. *Freshw. Mollusk Biol. Conserv.* **2019**, *22*, 70–80. [[CrossRef](#)]
44. Altschul, S.F.; Gish, W.; Miller, W.; Myers, E.W.; Lipman, D.J. Basic Local Alignment Search Tool. *J. Mol. Biol.* **1990**, *215*, 403–410. [[CrossRef](#)]